

Cite this article as: Saemann L, Zubarevich A, Wenzel F, Soethoff J, Loganathan S, Korkmaz-Icöz S *et al.* Impact of skeletonized harvesting of the internal thoracic artery on intrasternal microcirculation considering preparation quality. *Interact CardioVasc Thorac Surg* 2021;33:779–83.

## Impact of skeletonized harvesting of the internal thoracic artery on intrasternal microcirculation considering preparation quality

Lars Saemann<sup>a,b,c,\*</sup>, Alina Zubarevich<sup>d</sup>, Folker Wenzel<sup>c</sup>, Jasmin Soethoff<sup>b</sup>, Sivakkanan Loganathan<sup>a,b</sup>,  
Sevil Korkmaz-Icöz<sup>b</sup>, Matthias Karck<sup>b</sup>, Gábor Szabó<sup>a,b</sup> and Gábor Veres<sup>a,b</sup>

<sup>a</sup> Department of Cardiac Surgery, University of Halle, Halle, Germany

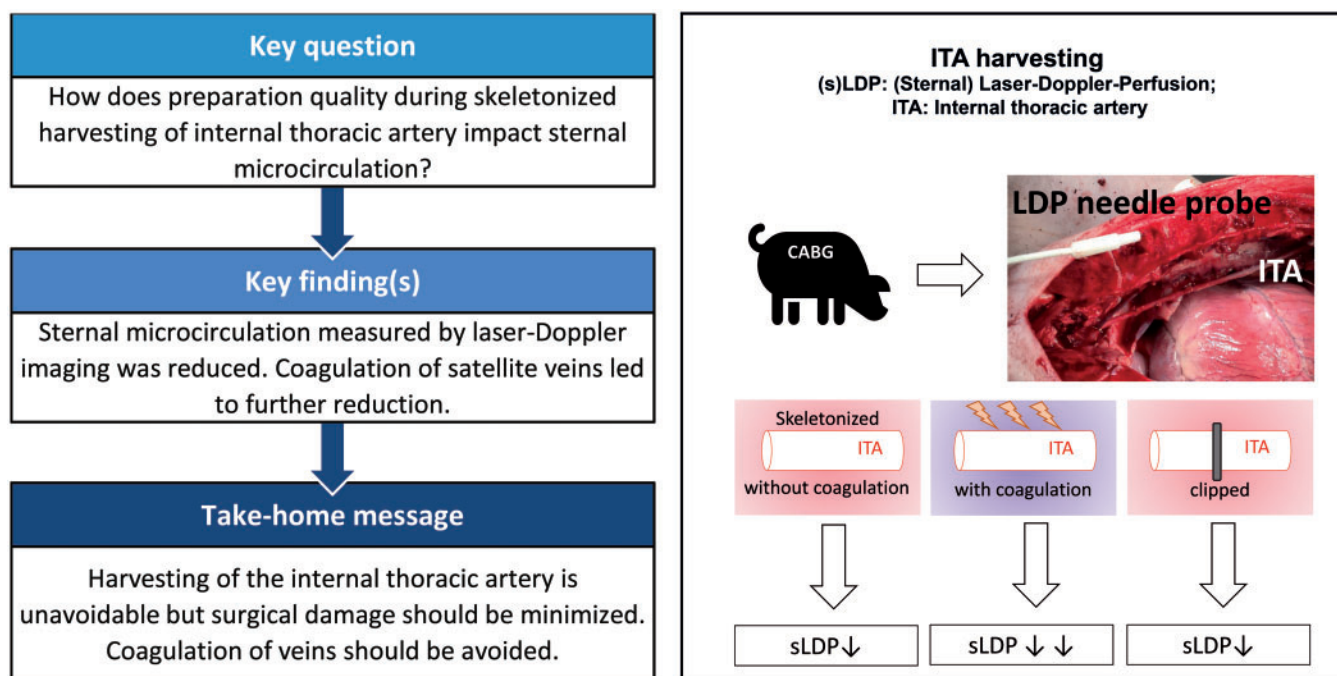
<sup>b</sup> Department of Cardiac Surgery, University of Heidelberg, Heidelberg, Germany

<sup>c</sup> Faculty Medical and Life Sciences, Furtwangen University, Villingen-Schwenningen, Germany

<sup>d</sup> Department of Thoracic and Cardiovascular Surgery, West German Heart and Vascular Center, University of Duisburg-Essen, Essen, Germany, Heidelberg

\* Corresponding author. Ernst-Grube-Straße 40, 06120 Halle (Saale), Germany. Tel: +49-1578-58-52-859; e-mail: lars.saemann@gmx.de, lars.saemann@uk-halle.de (L. Saemann).

Received 27 August 2020; received in revised form 15 March 2021; accepted 12 April 2021



### Abstract

**OBJECTIVES:** Previous studies have demonstrated the impact of internal thoracic artery (ITA) harvesting on microcirculation in parasternal tissues. However, the impact of skeletonized ITA harvesting on intrasternal microcirculation is unknown. Intrasternal tissue perfusion has been proven to be crucial for deep wound healing. Furthermore, the impact of different levels of surgical preparation quality on intrasternal microcirculation has not been investigated yet.

**METHODS:** Sternal microcirculation (sLDP) was monitored with a novel Laser Doppler Perfusion needle probe, while the ITA was skeletonized in a pig model. To mimic different levels of preparation quality, satellite veins were either coagulated or not during preparation. To show the effect of ideally avoiding any surgical manipulation on sLDP, the ITA was clipped in a third sham-harvested group.

Presented at the EACTS Annual Meeting, Barcelona, 8–10 October, 2020.

**RESULTS:** sLDP was reduced highly significant to 71 [standard deviation (SD): 9]% ( $P < 0.001$ ) after skeletonized harvesting of the ITA. Coagulation of the satellite veins as a detrimental surgical factor resulted in a significantly stronger reduction of sLDP to 56 (SD: 11)% ( $P < 0.05$ ) compared to sLDP with non-coagulated satellite veins. ITA clipping reduced sLDP highly significant to 71 (SD: 8)% ( $P < 0.001$ ) in the sham-operated group.

**CONCLUSIONS:** ITA harvesting markedly impairs microcirculation of the sternum but remains unavoidable when coronary artery bypass grafting should be performed. Nevertheless, excessive surgical damage and coagulation of satellite veins is avoidable and should be reduced to a minimum to minimize the risk of deep sternal wound healing complications.

**Keywords:** CABG • Sternal microcirculation • Skeletonized harvesting • Internal thoracic artery • Internal mammary artery

## ABBREVIATIONS

|        |                                    |
|--------|------------------------------------|
| CABG   | Coronary artery bypass grafting    |
| ITA    | Internal thoracic artery           |
| LDPM   | Laser Doppler Perfusion Monitoring |
| r-sLDP | Relative sLDP                      |
| SD     | Standard deviation                 |
| sLDP   | Sternal microcirculation           |

## INTRODUCTION

Coronary artery bypass grafting (CABG) is a common cardiac surgical intervention to treat coronary heart disease. The internal thoracic artery (ITA), saphenous vein or radial artery is harvested and used to bridge the stenosis of the native coronary artery during CABG [1, 2]. In skeletonized harvesting of ITA, the vessel is completely separated from the surrounding tissue, fascia, as well as internal thoracic vein. In comparison to preparation of the ITA as a pedicle skeletonized harvesting has been shown to reduce sternal complications [3–5]. So far, only a few studies investigated sternal microcirculation during ITA harvesting [6, 7]. However, only the perfusion in retro- and poststernal tissue has been observed [6, 7]. The impact of skeletonized harvesting of ITA on intrasternal microcirculation has not been investigated yet. Besides, we hypothesize that different levels of preparation quality within the skeletonized technique have an additional impact on sternal microcirculation.

## METHODS

### Animal preparation and anaesthesia

In an experimental model of CABG surgery, the ITA of healthy pigs with a body weight of 45–55 kg was harvested. The investigations were reviewed and approved by the local Ethical Committee for Animal Experimentation. Pigs were anaesthetized with Ketamine (Bremer Pharma, Warburg, Germany) and Midazolam (Hameln pharma plus, Hameln, Germany). After intubation, anaesthesia was maintained with Propofol 2% (Fresenius Kabi, Bad Homburg, Germany) through the ear vein. Ventilation was adjusted to maintain a partial pressure of oxygen of around 180–220 mmHg and a partial pressure of carbon dioxide of 35–45 mmHg. Arterial vascular access was achieved through femoral artery to monitor arterial blood pressure. Venous vascular access was achieved through femoral vein to enable fluid administration with Ringer's lactate if necessary. Blood gas samples were taken

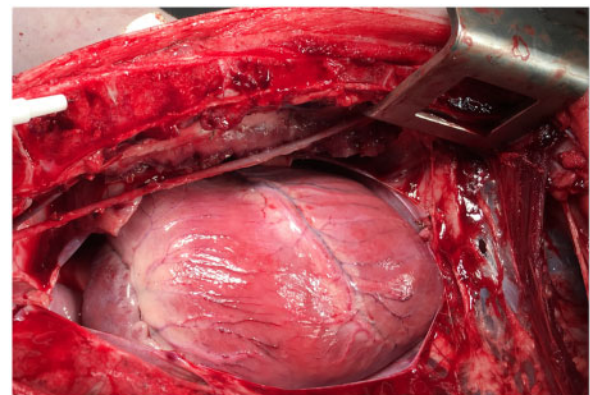
every 30 min to observe the physiological status of the pig. During ITA harvesting, the mean arterial blood pressure was kept constant without use of any catecholamines or inotropic substances around 80 mmHg.

### Surgical technique

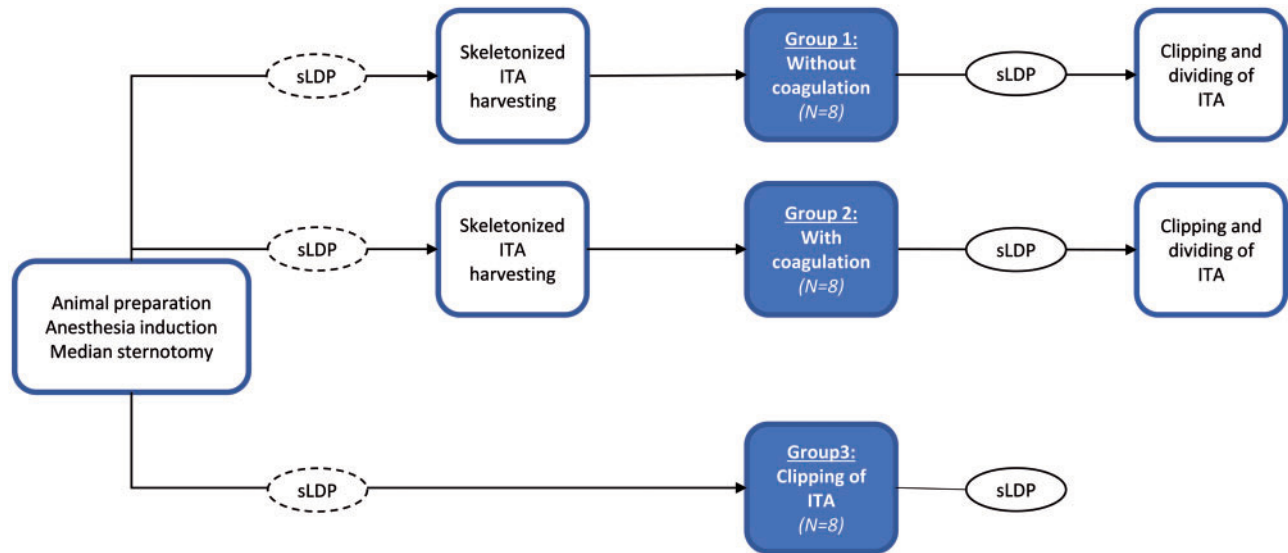
After median sternotomy the ITA was harvested by skeletonizing technique (Fig. 1). Surrounding tissue, including satellite veins, was either electrocoagulated ( $N = 8$ ) or not ( $N = 8$ ), according to different levels of preparation quality (Fig. 2). Before the ITA was clipped and divided heparin was administered to avoid coagulation. To mimic a perfect preparation quality, the total avoidance of any surgical manipulation during ITA harvesting was achieved by clip ligation on the proximal side of the vessel in a third sham-harvested group ( $N = 8$ ).

### Monitoring of intrasternal microcirculation

We inserted a novel Laser Doppler Perfusion needle probe (Perimed, Järfälla-Stockholm, Sweden) into the sternum to monitor sternal microcirculation (sLDP) during ITA harvesting (Fig. 1). The probe contained a silica fibre of 0.125 mm in diameter and the fibre separation was given with 0.25 mm, according to manufacturer's information. The tip of the probe was characterized with a thin dimension of 0.45 mm in diameter and 53 mm in length. The needle probe was combined with the compatible Peri Flux 5000 (Perimed, Järfälla-Stockholm, Sweden) Laser Doppler Perfusion Monitoring (LDPM) System. The time constant, also known as the interval between 2 measurements of the LDPM System, was set at 0.2 s. The measurement signal was typically expressed in relative units. For each pig a baseline measurement was performed previously to the intervention and another



**Figure 1:** Invasive measurement of intrasternal microcirculation.



**Figure 2:** Groups. Dotted lines represent the baseline measurement to which a subsequent measurement is compared to. ITA: internal thoracic artery. sLDP: sternal microcirculation.

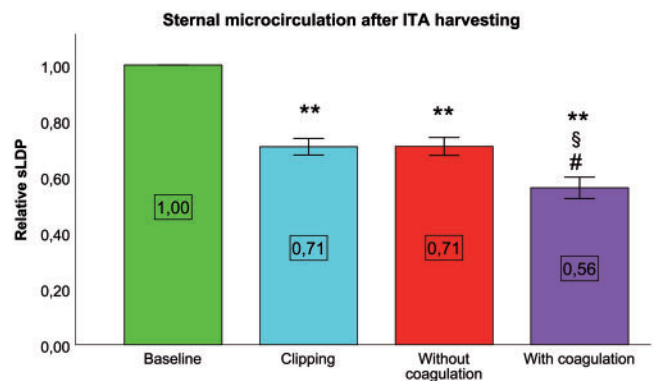
measurement was performed after the intervention. Finally, a relative sLDP (r-sLDP) was calculated as a ratio of sLDP after the intervention to baseline sLDP before the intervention [8, 9]. Therefore, sLDP was measured once before and once after ITA harvesting with or without coagulation and once before and once after clipping (Fig. 2).

## Statistical analysis

Statistical analysis was performed using IBM SPSS Statistics for Windows (Version 20.0, IBM Corp., Armonk, NY, USA). Data were presented as mean with standard deviation (SD). Homogeneity of variances for the comparison of all intervention groups was tested by Levene test, followed by one-way analysis of variance with Games-Howell adjusted  $P$ -values according to the presence of inhomogeneity of variances. A value of  $P < 0.05$  was considered as statistically significant and a value of  $P < 0.001$  was considered as statistically highly significant.

## RESULTS

Sternal microcirculation was monitored in 24 subjects. Satellite veins were either coagulated ( $N = 8$ ) or not ( $N = 8$ ) during harvesting of ITA. In a third group ( $N = 8$ ), the ITA was ligated by clipping to mimic total avoidance of surgical manipulation. r-sLDP was reduced highly significant to 56 (SD: 11)% after harvesting with coagulation, to 71 (SD: 9)% after harvesting without coagulation and to 71 (SD: 8)% after clipping, each compared to baseline-r-sLDP level before harvesting (Fig. 3). Furthermore, r-sLDP was impaired significantly more by harvesting with coagulation (Fig. 3), when compared to both, after clipping ( $P = 0.041$ ) or after harvesting without coagulation ( $P = 0.046$ ). Clipping and harvesting without coagulation of the satellite veins did not result in a different reduced r-sLDP.



**Figure 3:** Sternal microcirculation. \*\* $P < 0.001$  versus baseline; # $P < 0.05$  versus harvesting without coagulation; § $P < 0.05$  versus clipping (sham harvesting); All  $N = 8$ . ITA: internal thoracic artery. sLDP: sternal microcirculation.

## DISCUSSION

Various studies, with a network meta-analysis of clinical outcomes by Gaudino *et al.* ahead, showed best long-term graft patency of ITA when compared to saphenous vein in CABG [10, 11]. Although the superiority in graft patency is a major advantage of ITA, the disadvantages are deep sternal wound infections and healing disorder after CABG [12, 13]. After bilateral ITA harvesting wound healing disorder is even more profound as shown by a meta-analysis by Dai and colleagues [14, 15]. Accordingly, optimizations of the surgical technique during ITA harvesting were developed. Peterson *et al.* [16] showed superiority of skeletonized ITA harvesting compared with non-skeletonized harvesting regarding deep sternal wound infections in a large clinical trial. De Paulis *et al.* [17] identified pedicled bilateral harvesting to be an independent risk factor for deep and superficial sternal wound infections.

Bones are highly vascularized and provided with a constant blood flow [18]. Thus, regeneration and healing of bones is highly depended on bone blood flow. Restoration of tissue perfusion in bones has been proven to be crucial for healing of fractures [19]. Consequently, we assume that deep sternal wound healing

majorly depends on preservation of sternal blood flow. Nevertheless, monitoring of intrasternal blood flow was not performed so far. Only the blood flow in retro and parasternal tissue was monitored in 2 clinical trials during ITA harvesting [6, 7]. Since the superiority of skeletonized versus non-skeletonized harvesting has already been shown regarding deep sternal wound healing disorders in clinical trials, we investigated the impact of further optimization of the skeletonized harvesting technique. Therefore, we compared intrasternal blood flow after harvesting with and without coagulation of satellite veins by monitoring of sLDP.

The ITA is the main arterial vessel to perfuse sternal tissue. Therefore, it is reasonable that harvesting of ITA impairs r-sLDP dramatically. This result is also consistent with the impaired parasternal microcirculation after ITA harvesting, published by Knobloch *et al.* Since also other arterial vessels are responsible for a minor supply of the sternum [20], perfusion of the sternum was not totally stopped. Venules facilitate the venous drainage in the microcirculatory system [21].

Coagulation of satellite veins probably inhibits drainage of venules and consequently also of the capillary bed, leading to a decreased blood flow in the arterial part of the microcirculatory system and lowering the overall r-sLDP. This finally approved our hypothesis that preparation quality has an impact on maintenance of sLDP.

Sham harvesting of ITA by clipping the proximal part prevents the surrounding tissue from any surgical damage. Despite the avoidance of surgical damage inhibiting blood flow through ITA was clearly expected to reduce r-sLDP. Interestingly, sham harvesting may lead to a comparable reduction of sLDP to harvesting without coagulation. This leads to the suggestion that skeletonized harvesting without coagulation of satellite veins results in a minimized risk of sLDP-impairment and that further optimization of preparation technique is not necessary.

## Clinical relevance

The novel Laser Doppler Perfusion needle probe, which was used in this study, is not approved to be used in a clinical setting. Nevertheless, the experimental CABG operation in a large animal model was already presented to be clinically relevant [22]. Moreover, monitoring of sLDP by routine during ITA harvesting in every patient would only be beneficial until a sufficiently high level of preparation quality would have been achieved by the surgeon. As an excessive surgical damage during preparation would not be reversible, measurement of sLDP during ITA harvesting in a clinical setting would only be useful as a monitoring system for the preparation expertise of the surgeon. Consequently, it could be involved into training of young surgeons.

**Laser Doppler Perfusion Monitoring.** LDPM is known to be disadvantaged by its susceptibility to motion artefacts [8]. Based on our experience in LDPM we know, motion artefacts can either be caused by the subject, by the investigator or both. Especially in moving organs like heart LDPM is complicated [23]. In our study, motion artefacts by the subject or organ could be avoided because the thorax did not move as the lung was artificially ventilated and could swing freely in the opened thorax. Motion artefacts by the surgeon could also have been avoided by applying a

time point-based comparison of perfusion instead of an observation of perfusion course. During the short period of sLDP measurements, the surgeon needed to stay away from the side of measurement.

Invasive measurement of tissue perfusion generates structural damage by insertion of the probe. However, the needle probe used in this study is of very thin dimensions so that insertion is associated with less tissue trauma. In addition, LDPM technology could be of special advantage because the place of measurement is located at a short distance ahead to the top of the probe tip [8]. Therefore, we conclude that a biased sLDP due to probe insertion into the sternum can be excluded out of technical properties of the technology and probe.

## Limitations

The only restriction this study is limited by is the fact that it was conducted in an experimental setting with pigs and not in a clinical environment on humans.

## CONCLUSION

ITA harvesting markedly impairs microcirculation of the sternum but remains unavoidable when arterial revascularization of the coronary arteries should be performed. Nevertheless, excessive surgical damage and coagulation of satellite veins is avoidable and should be reduced to a minimum to prevent sLDP from further significant decline.

## ACKNOWLEDGEMENT

We kindly want to thank Patricia Kraft for her technical assistance.

## Funding

This work did not receive any specific funding. LS. is the first fellow of the Josef Güttler Scholarship by the German Society for Cardiovascular Engineering/Deutsche Gesellschaft für Kardiotechnik.

**Conflict of interest:** none declared.

## Author contributions

**Lars Saemann:** Conceptualization; Data curation; Formal analysis; Investigation; Methodology; Software; Supervision; Visualization; Writing—original draft. **Alina Zubarevich:** Investigation; Methodology. **Folker Wenzel:** Methodology; Supervision; Writing—review & editing. **Jasmin Soethoff:** Investigation. **Sivakkanan Loganathan:** Methodology. **Sevil Korkmaz-Icöz:** Methodology. **Matthias Karck:** Resources; Supervision. **Gábor Szabó:** Conceptualization; Writing—review & editing. **Gábor Veres:** Conceptualization; Investigation; Methodology; Supervision; Writing—review & editing.

## Reviewer information

Interactive CardioVascular and Thoracic Surgery thanks Johannes M. Albes, Anton Tomsic and the other, anonymous reviewer(s) for their contribution to the peer review process of this article.



## REFERENCES

- [1] Kieser TM, Rose MS, Aluthman U, Narine K. Quicker yet safe: skeletonization of 1640 internal mammary arteries with harmonic technology in 965 patients. *Eur J Cardiothorac Surg* 2014;45:e142–e150.
- [2] Akca F, Lam KY, Verberkmoes N, Lathauwer I. D, Soliman-Hamad M, van Straten B. Predictive value of great saphenous vein mapping prior to endoscopic harvesting in coronary artery bypass surgery. *Interact CardioVasc Thorac Surg* 2020.
- [3] Matsa M, Paz Y, Gurevitch J, Shapira I, Kramer A, Pevny D *et al.* Bilateral skeletonized internal thoracic artery grafts in patients with diabetes mellitus. *J Thorac Cardiovasc Surg* 2001;121:668–74.
- [4] Athanasiou T, Crossman M-C, Asimakopoulos G, Cherian A, Weerasinghe A, Glenville B *et al.* Should the internal thoracic artery be skeletonized? *Ann Thorac Surg* 2004;77:2238–46.
- [5] Benedetto U, Altman DG, Gerry S, Gray A, Lees B, Pawlaczyk R *et al.*; Arterial Revascularization Trial Investigators. Pedicled and skeletonized single and bilateral internal thoracic artery grafts and the incidence of sternal wound complications: insights from the Arterial Revascularization Trial. *J Thorac Cardiovasc Surg* 2016;152:270–6.
- [6] Kamiya H, Akhyari P, Martens A, Karck M, Haverich A, Lichtenberg A. Sternal microcirculation after skeletonized versus pedicled harvesting of the internal thoracic artery: a randomized study. *J Thorac Cardiovasc Surg* 2008;135:32–7.
- [7] Knobloch K, Lichtenberg A, Pichlmaier M, Mertsching H, Krug A, Klima U *et al.* Microcirculation of the sternum following harvesting of the left internal mammary artery. *Thorac Cardiovasc Surg* 2003;51:255–9.
- [8] Leahy MJ, Mul FF. D, Nilsson GE, Maniewski R. Principles and practice of the laser-Doppler perfusion technique. *Technol Health Care* 1999;7:143–62.
- [9] Saemann L, Wenzel F. Cutaneous microcirculation during operations with a cardiopulmonary bypass. *Clin Hemorheol Microcirc* 2018;69:13–21.
- [10] Goldman S, Zadina K, Moritz T, Ovitt T, Sethi G, Copeland JG *et al.* Long-term patency of saphenous vein and left internal mammary artery grafts after coronary artery bypass surgery: results from a Department of Veterans Affairs Cooperative Study. *J Am Coll Cardiol* 2004;44:2149–56.
- [11] Gaudino M, Lorusso R, Rahouma M, Abouarab A, Tam DY, Spadaccio C *et al.* Radial artery versus right internal thoracic artery versus saphenous vein as the second conduit for coronary artery bypass surgery: a network meta-analysis of clinical outcomes. *J Am Heart Assoc* 2019;8:e010839.
- [12] Grossi EA, Esposito R, Harris LJ, Crooke GA, Galloway AC, Colvin SB *et al.* Sternal wound infections and use of internal mammary artery grafts. *J Thorac Cardiovasc Surg* 1991;102:342–6; discussion 346–7.
- [13] Nakano J, Okabayashi H, Hanyu M, Soga Y, Nomoto T, Arai Y *et al.* Risk factors for wound infection after off-pump coronary artery bypass grafting: should bilateral internal thoracic arteries be harvested in patients with diabetes? *J Thorac Cardiovasc Surg* 2008;135:540–5.
- [14] Dai C, Lu Z, Zhu H, Xue S, Lian F. Bilateral internal mammary artery grafting and risk of sternal wound infection: evidence from observational studies. *Ann Thorac Surg* 2013;95:1938–45.
- [15] Gansera B, Schmidler F, Gillrath G, Angelis I, Wenke K, Weingartner J *et al.* Does bilateral ITA grafting increase perioperative complications? Outcome of 4462 patients with bilateral versus 4204 patients with single ITA bypass. *Eur J Cardiothorac Surg* 2006;30:318–23.
- [16] Peterson MD, Borger MA, Rao V, Peniston CM, Feindel CM. Skeletonization of bilateral internal thoracic artery grafts lowers the risk of sternal infection in patients with diabetes. *J Thorac Cardiovasc Surg* 2003;126:1314–9.
- [17] De Paulis R, de Notaris S, Scaffa R, Nardella S, Zeitani J, Del Giudice C *et al.* The effect of bilateral internal thoracic artery harvesting on superficial and deep sternal infection: the role of skeletonization. *J Thorac Cardiovasc Surg* 2005;129:536–43.
- [18] Tomlinson RE, Silva MJ. Skeletal blood flow in bone repair and maintenance. *Bone Res* 2013;1:311–22.
- [19] Gerstenfeld LC, Cullinane DM, Barnes GL, Graves DT, Einhorn TA. Fracture healing as a post-natal developmental process: molecular, spatial, and temporal aspects of its regulation. *J Cell Biochem* 2003;88:873–84.
- [20] Berdajs D, Zünd G, Turina MI, Genoni M. Blood supply of the sternum and its importance in internal thoracic artery harvesting. *Ann Thorac Surg* 2006;81:2155–9.
- [21] Mrowietz C, Franke RP, Pindur G, Wolf U, Jung F. Reference range and variability of Laser-Doppler-Fluxmetry. *Clin Hemorheol Microcirc* 2017;67:347–53.
- [22] Veres G, Schmidt H, Hegedús P, Korkmaz-Icöz S, Radovits T, Loganathan S *et al.* Is internal thoracic artery resistant to reperfusion injury? Evaluation of the storage of free internal thoracic artery grafts. *J Thorac Cardiovasc Surg* 2018;156:1460–9.
- [23] Karlsson MGD, Fors C, Wårdell K, Casimir-Ahn H. Myocardial perfusion monitoring during coronary artery bypass using an electrocardiogram-triggered laser Doppler technique. *Med Biol Eng Comput* 2005;43:582–8.